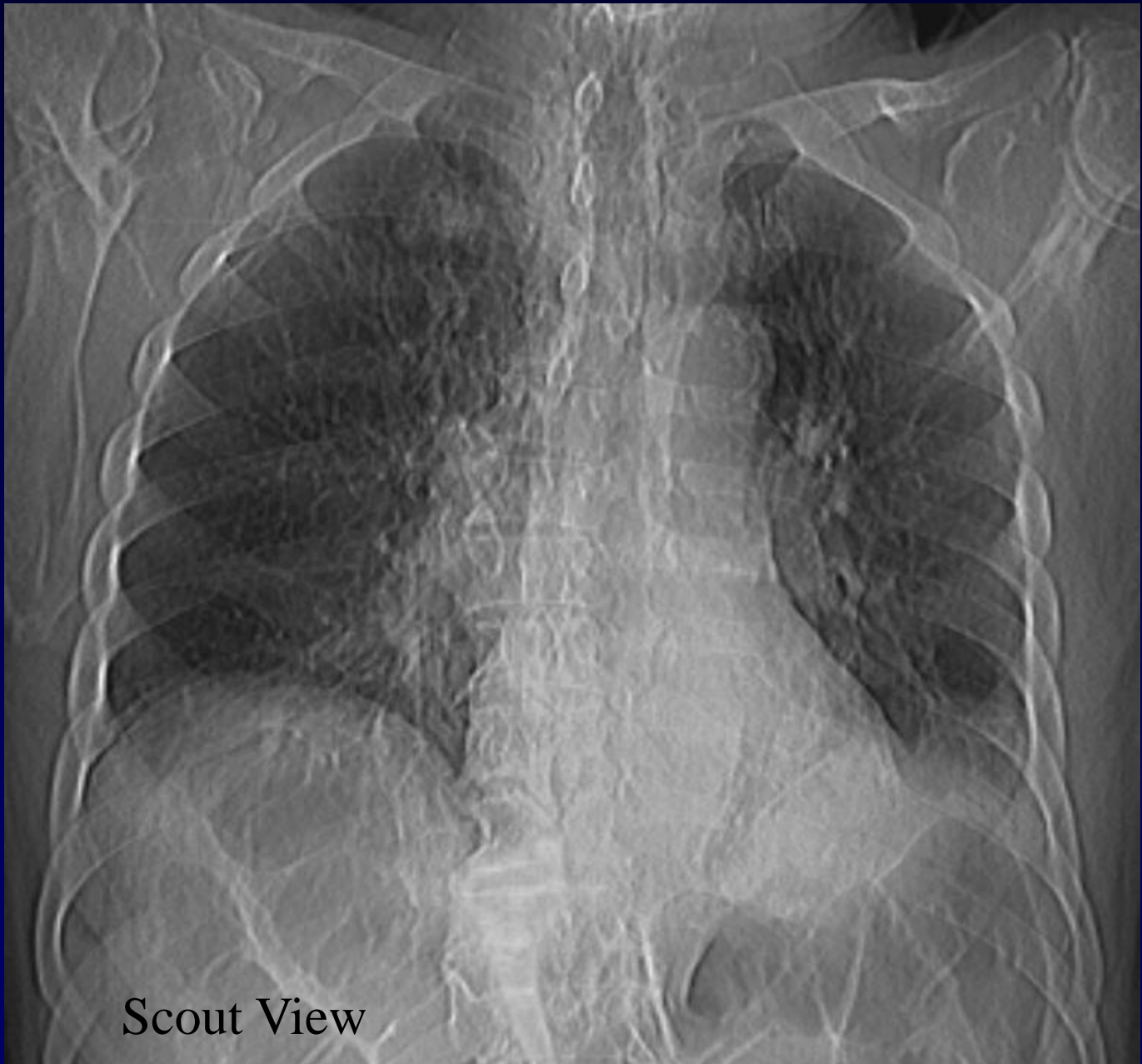




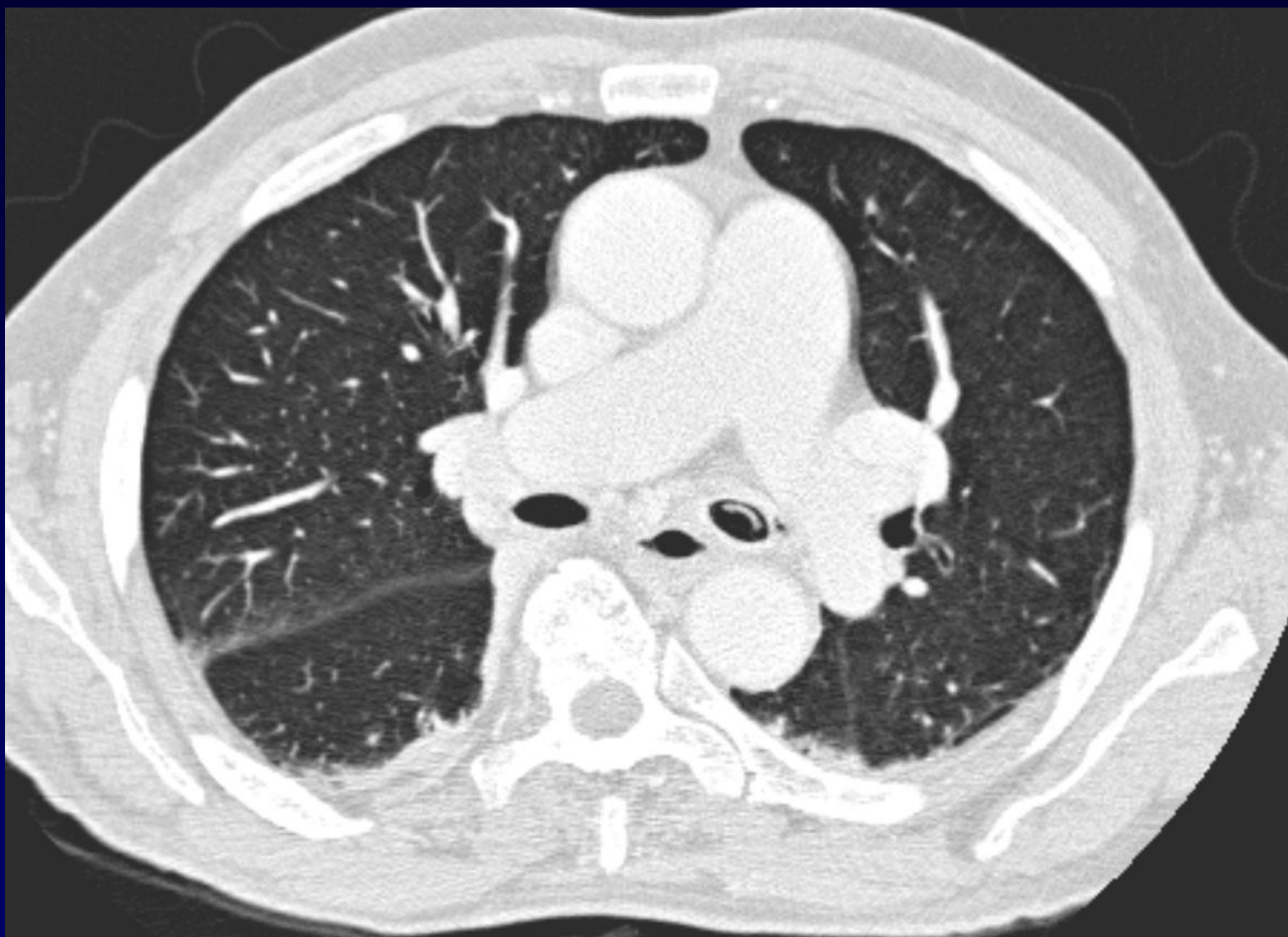
Alexis LACOUT

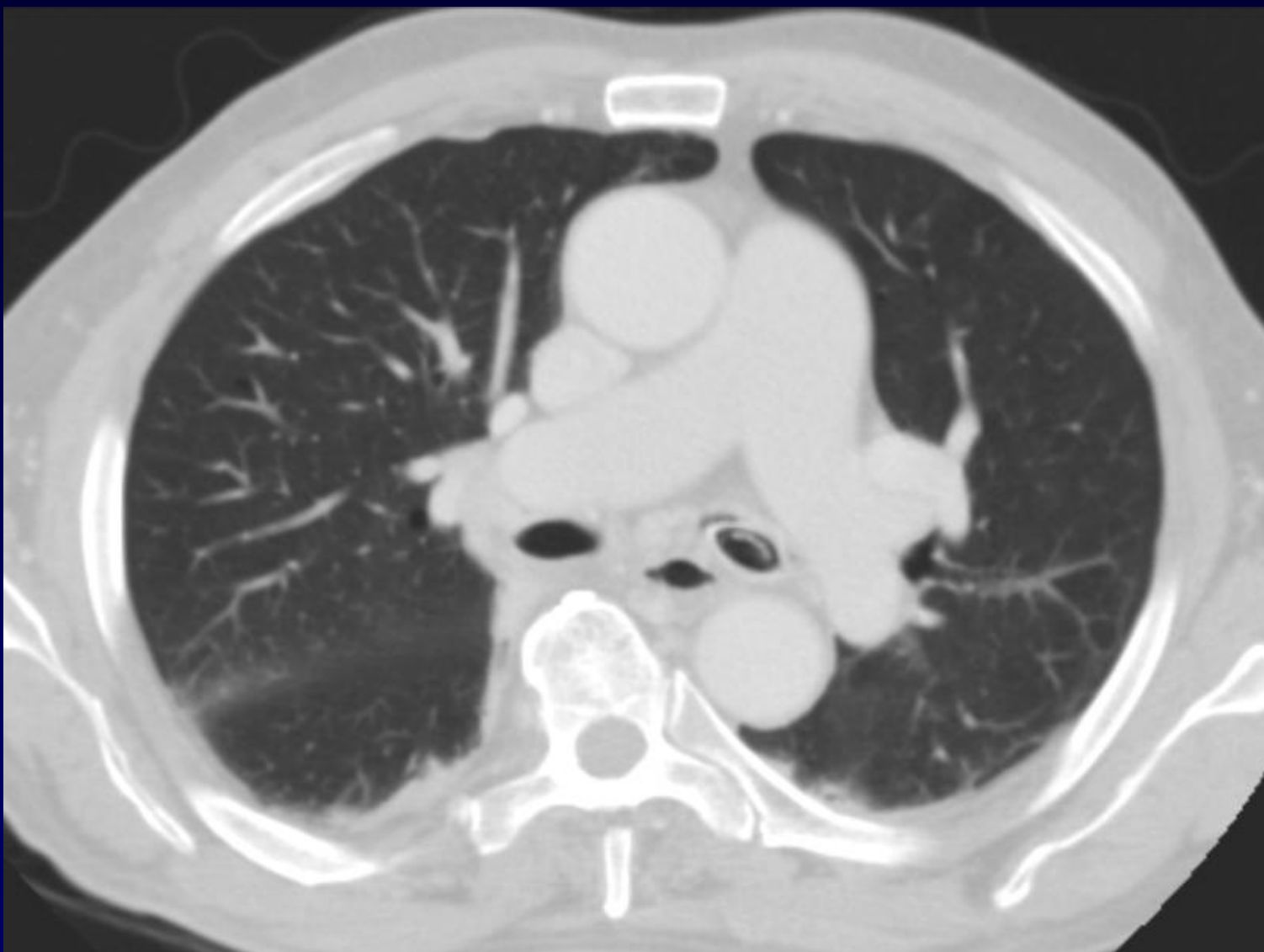
Homme de 91 ans

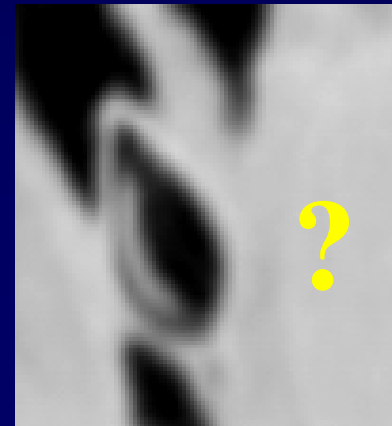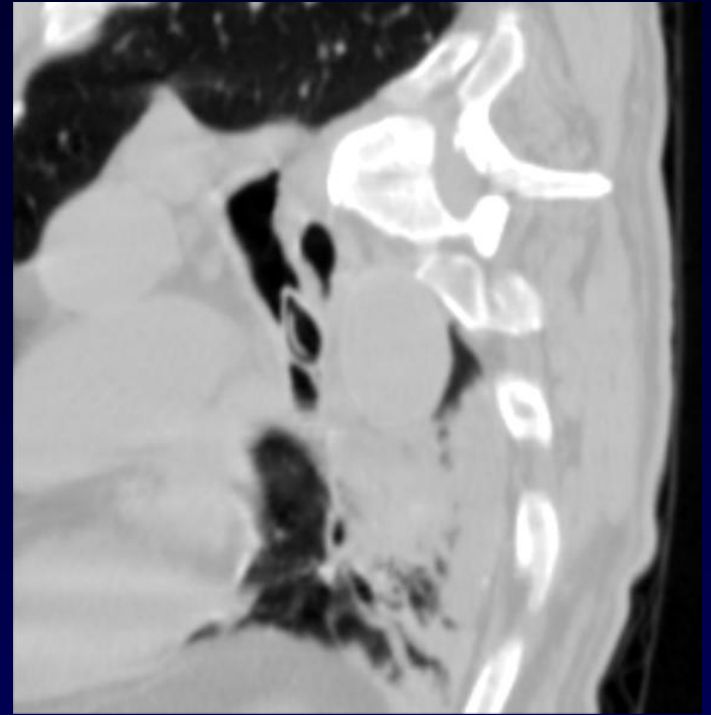
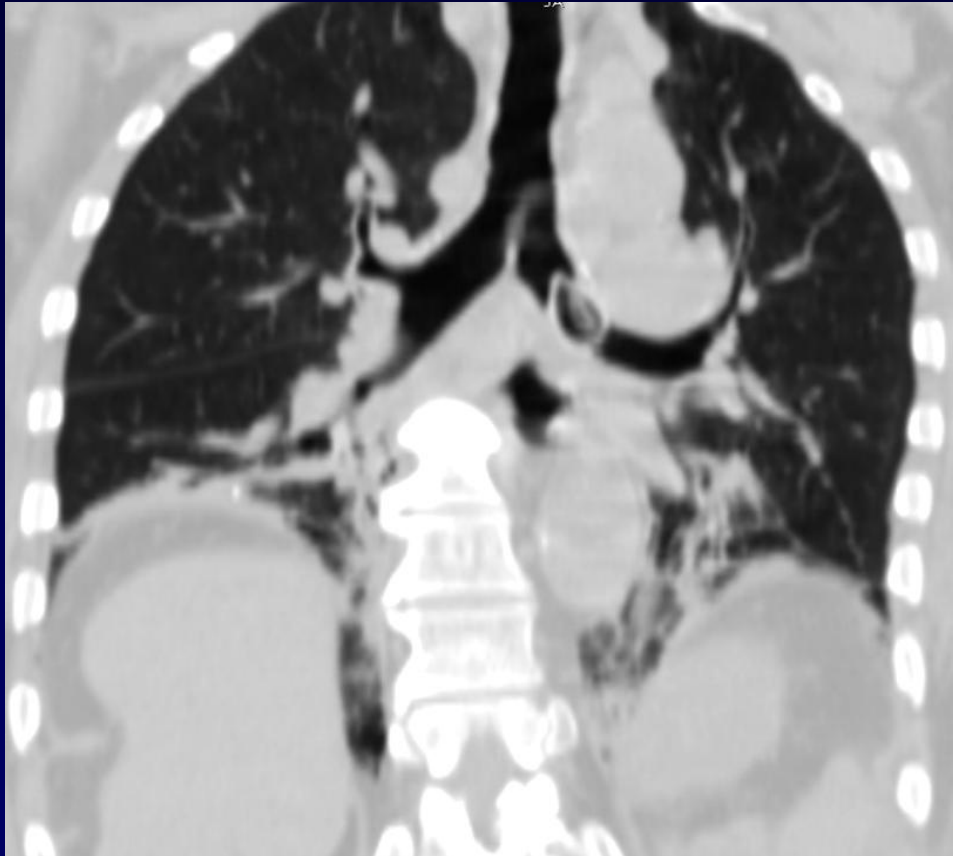
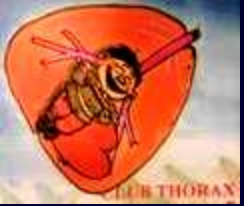Gêne respiratoire survenant au cours d'un repas



Scout View

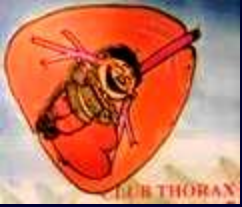







Diagnostic ?

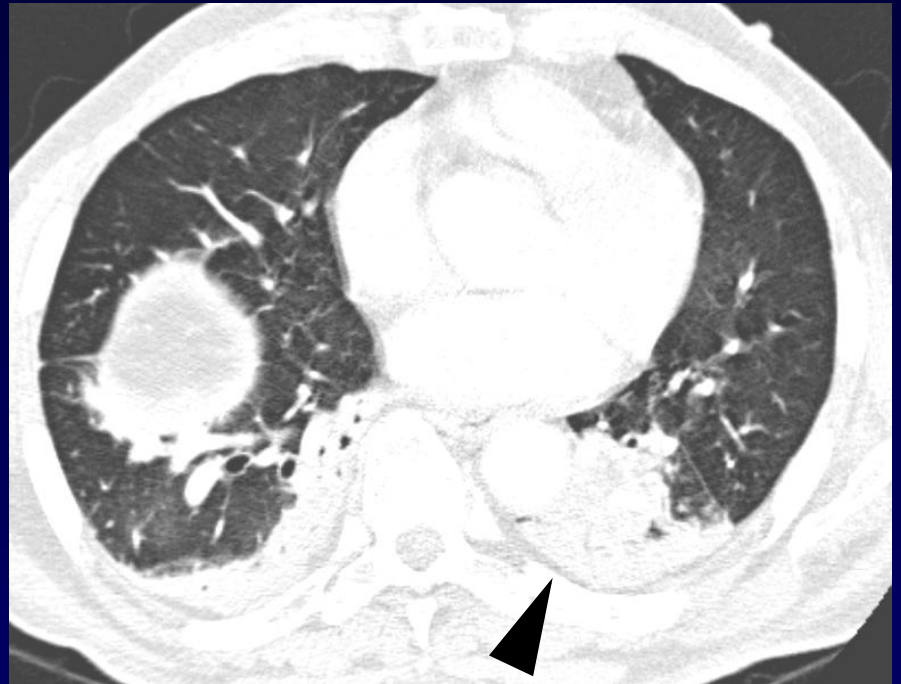
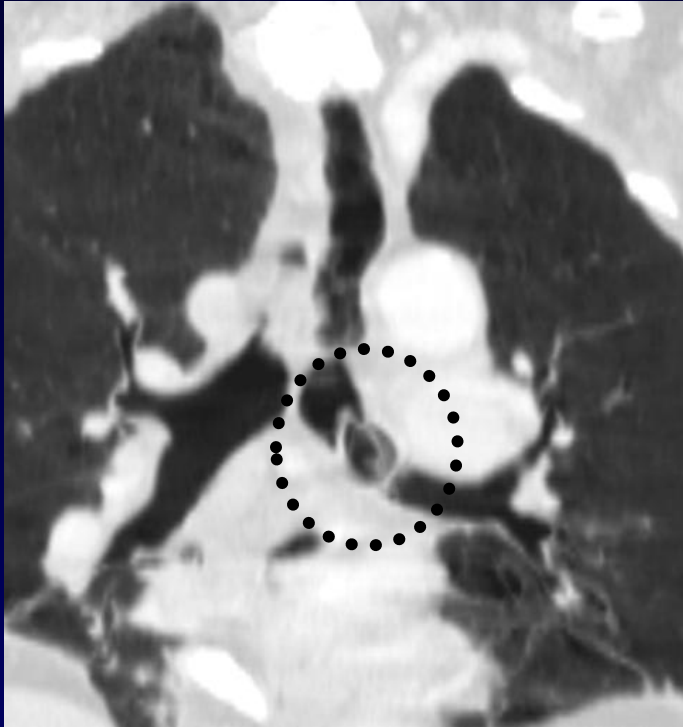
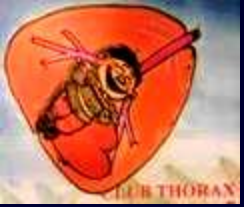Diagnostic

Corps étranger intra-bronchique

Noyau d'abricot

Extraction endoscopique



Noyau dans la bronche souche gauche (cercle) ; collapsus du lobe inférieur gauche (tête de flèche)